

MaioRegen™

Biojoint System 

Osteochondral regeneration.
Getting to the core
of the problem.





MaioRegen™



- Bio-mimetic, biointegratable and resorbable
- Flexible and easy to shape
- Straightforward “one-step” procedure
- Promotes a guided osteo-chondral regeneration





Driven by nature, powered by technology.

Lesions of the joint surface are a very common clinical challenge, frequently diagnosed also in young people. If untreated, they may degenerate into chronic, disabling conditions that can be addressed only by an invasive approach.

In most cases, an articular cartilage damage implies a simultaneous suffering of the sub-chondral bone structure. To guarantee the successful restoration of an healthy and functional joint, we should go "to the core of the problem".

Maioregen is a new therapeutic concept, inspired by nature and shaped by state-of-the-art Nanotechnologies. It promotes and guides an effective bone and cartilage regeneration, thus restoring the natural joint physiology.

Composition and structure

MaioRegen is a three-dimensional matrix which mimics the entire osteo-cartilaginous tissue: cartilage, tide-mark and sub-chondral bone.

It is a monolithic, multi-layer scaffold: the superficial layer consists of deantigenated type I equine collagen and resembles the cartilaginous tissue, while the lower layer consists mostly of magnesium-enriched hydroxyapatite (Mg-HA), and simulates the sub-chondral bone structure. The intermediate layer, composed of Mg-HA and collagen, reproduces the tide-mark.

MaioRegen is obtained through a unique, patented process, the result of the cooperation between Finceramica and internationally recognized research centres.



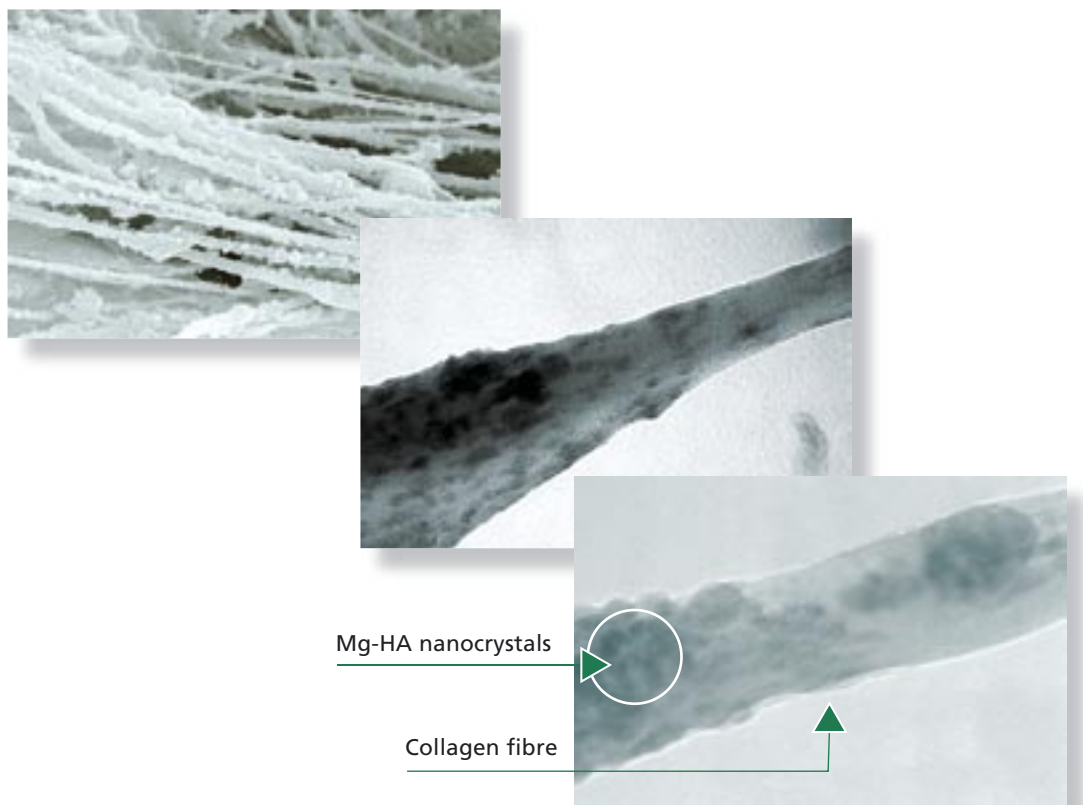
Biomimetism



Biomimetic is a substance recognised and accepted by the body as self, without triggering any immune response.

The peculiar chemical composition and structure make MaioRegen a fully biomimetic scaffold. The “chemical” biomimetism is given by using collagen macromolecules and Mg-HA nanocrystals, combined through an innovative nucleation mechanism which resembles the biologic neo-ossification process.

The “structural” biomimetism is given by the characteristic orientation of collagen fibres, organised as they would be within the human osteo-chondral tissue.



Sequence of progressive EM enlargements, highlighting both the micro- and nano-structure of MaioRegen sub-chondral layer.

Features



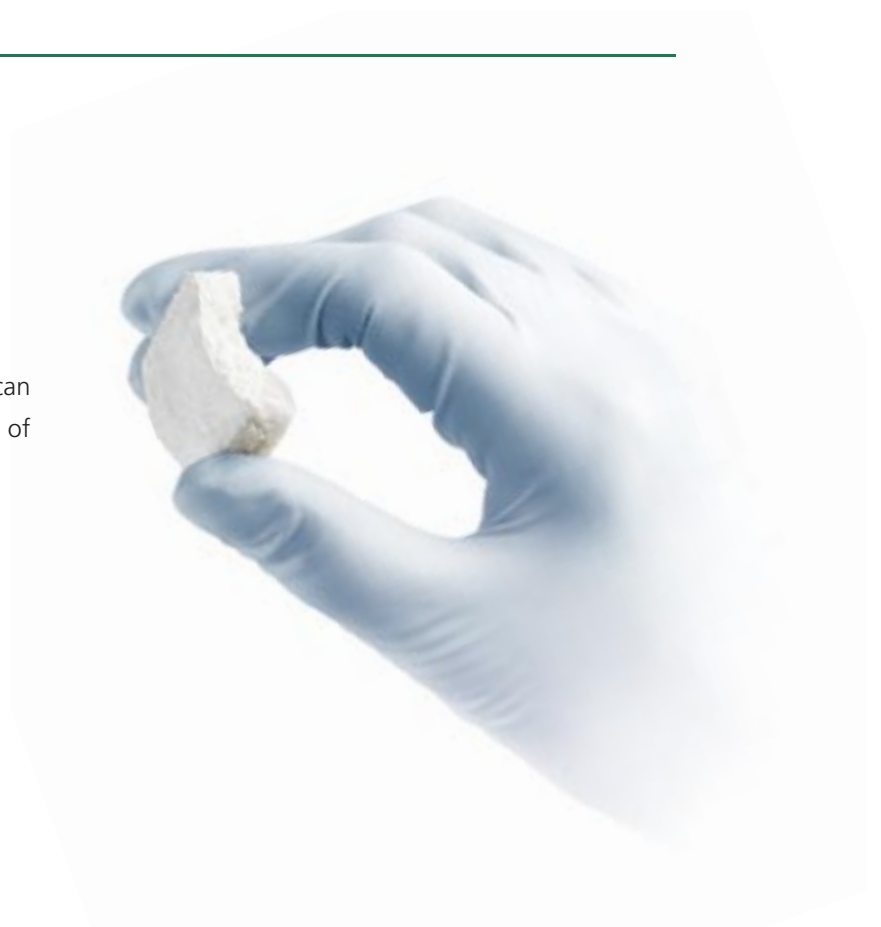Hydration

Thanks to its high porosity and hydrophilic properties, MaioRegen can quickly absorb biologic fluids (water uptake: 750%).

The device swelling provides for *in situ* solid self-stabilisation, without any further suturing or other fixation methods.

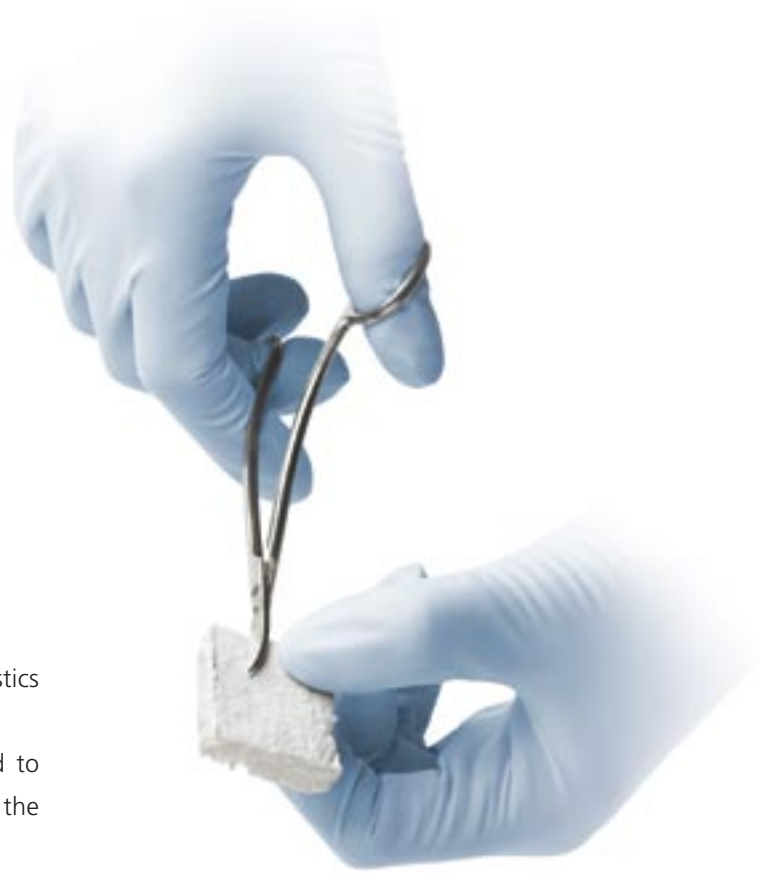
Flexibility

Flexible and elastic, MaioRegen can perfectly fit the anatomic curvature of the application site.



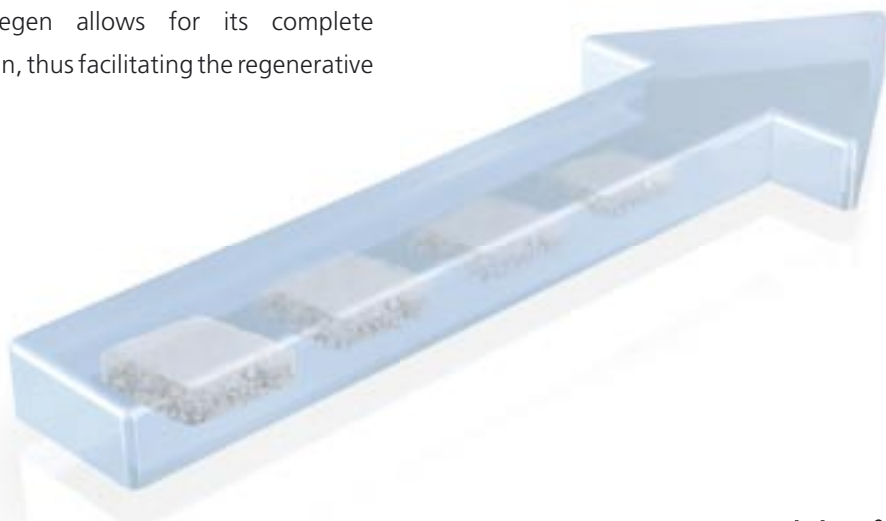
Conformability

Its peculiar chemical-physical characteristics make MaioRegen perfectly conformable. During surgery, it can be easily adapted to the defect dimensions and used even for the treatment of large lesions.



Degradability

The biomimetic chemical composition of MaioRegen allows for its complete degradation, thus facilitating the regenerative processes.





Biologic Rational

1




Cartilage layer

Tide-mark

Sub-condral layer

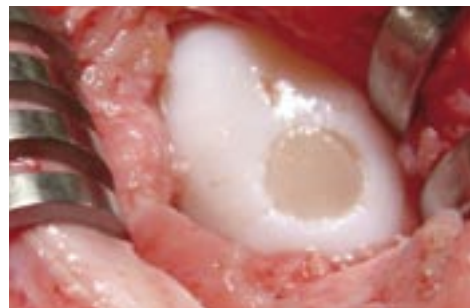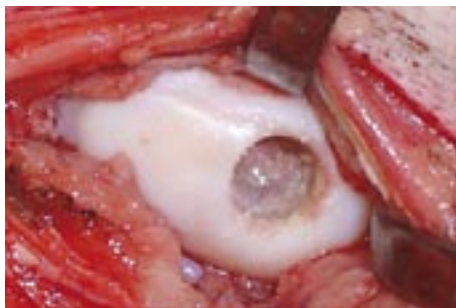


2



After curettage and preparation of the implant site so as to guarantee suitable marrow blood flow, MaioRegen is shaped according to the defect and applied with a slight pressure.

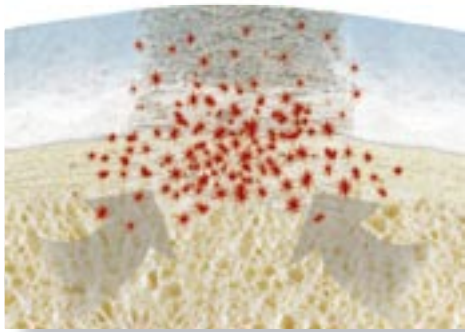
MaioRegen adapts perfectly to the lesion, restoring anatomic continuity and guaranteeing *in situ* self-stabilisation.



Pictures taken during an experimental study on a sheep model.

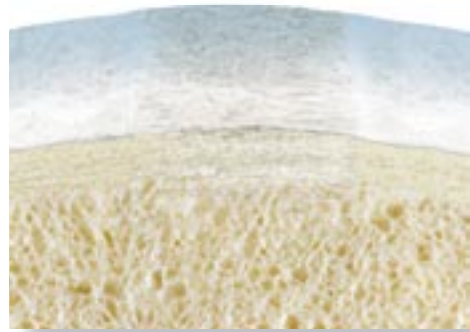


3

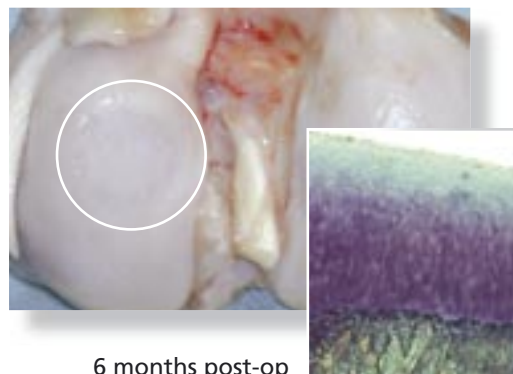
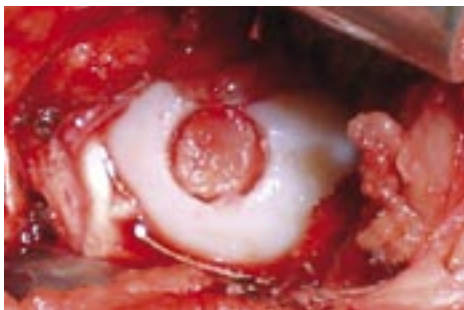

The porous structure and the chemical composition of MaioRegen favour cellular chemotaxis. The bone marrow-derived progenitor cells selectively adhere to the collagen fibres, colonising the entire scaffold thickness.

4





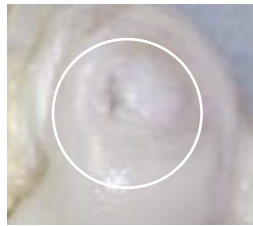
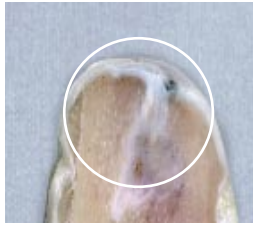

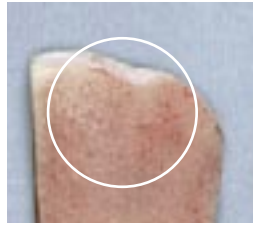
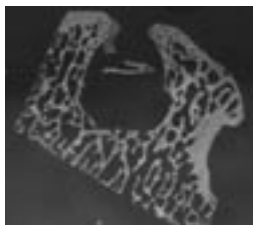
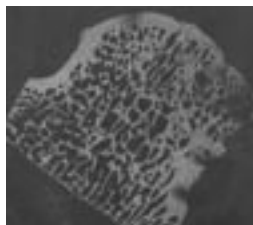
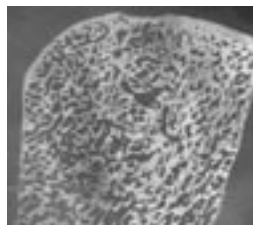

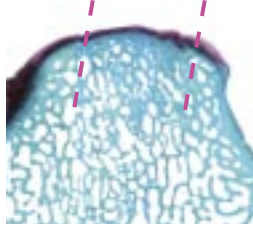
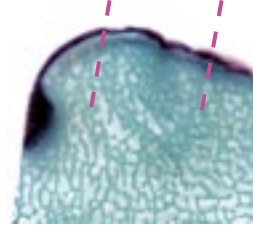
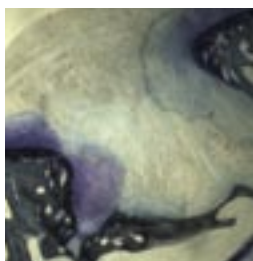
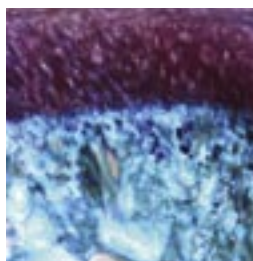
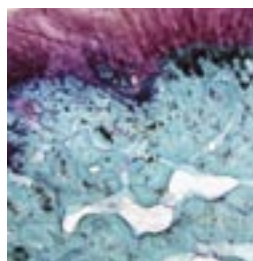
The adhered progenitor cells proliferate, differentiate and synthesise bone and cartilage matrix according to the organic-mineral gradient found inside the scaffold. The progressive reabsorption of MaioRegen and the simultaneous cell-mediated remodelling favour the complete regeneration of the osteo-cartilagenous tissue.



6 months post-op

Results

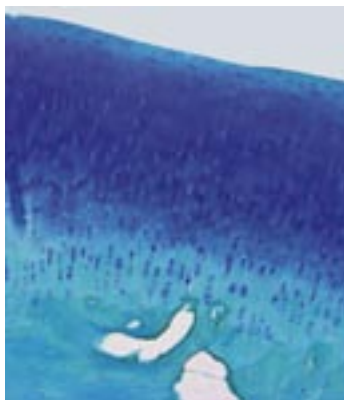The efficacy of MaioRegen has been demonstrated by an experimental study on a sheep model, comparing three different treatment groups: control (sham operated untreated lesion), MaioRegen, and autologous chondrocytes cultured onto MaioRegen.

| | CONTROL | MAIOREGEN | CHONDROCYTES CULTURED ONTO MAIOREGEN |
|--|---|--|---|
| <p>Macroscopic evaluation of condyles at 6 months post-op. Hyaline-like aspect of the newly-formed cartilage in all treatment groups.</p> |  |  |  |
| <p>Sagittal section of a condyle. Newly-formed fibrous tissue in the control group and well organised osteo-cartilaginous tissue in the two treatment groups.</p> |  |  |  |
| <p>Micro X-ray of the sagittal sections. The presence of newly-formed trabecular bone tissue is evident in the two treatment groups.</p> |  |  |  |
| <p>Histologic study. Well structured bone and cartilaginous tissues in the two treatment groups. Fibrous tissue and evident bone gap in the control.</p> |  |  |  |
| <p>Histologic detail. The two treatment groups show an ordered distribution of chondrocytes immersed in a "zonal" extra-cellular matrix, typical of hyaline articular cartilage. In the control, non-structured fibrous tissue.</p> |  |  |  |


The experimental study results show how MaioRegen, once implanted, is able to integrate with surrounding tissues and guarantee the regeneration of the entire damaged osteo-chondral compartment, with the formation of well structured bone tissue and hyaline-like cartilaginous tissue.

The group treated with MaioRegen displays results clearly equivalent to those of the group receiving MaioRegen combined with autologous chondrocytes.

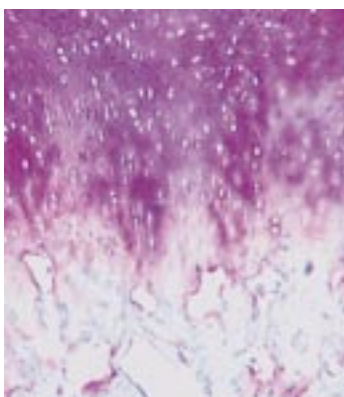
Histologic evaluation of MaioRegen



Histology of the newly-formed osteo-chondral tissue. A columnar and longitudinal arrangement of chondrocytes, respectively in the deep and superficial zones and a well organised trabecular bone tissue is shown.



Polarized light microscope analysis. In the deep chondral layer, collagenous fibres are arranged predominantly perpendicular to the articular surface, typical orientation of a mature tissue.



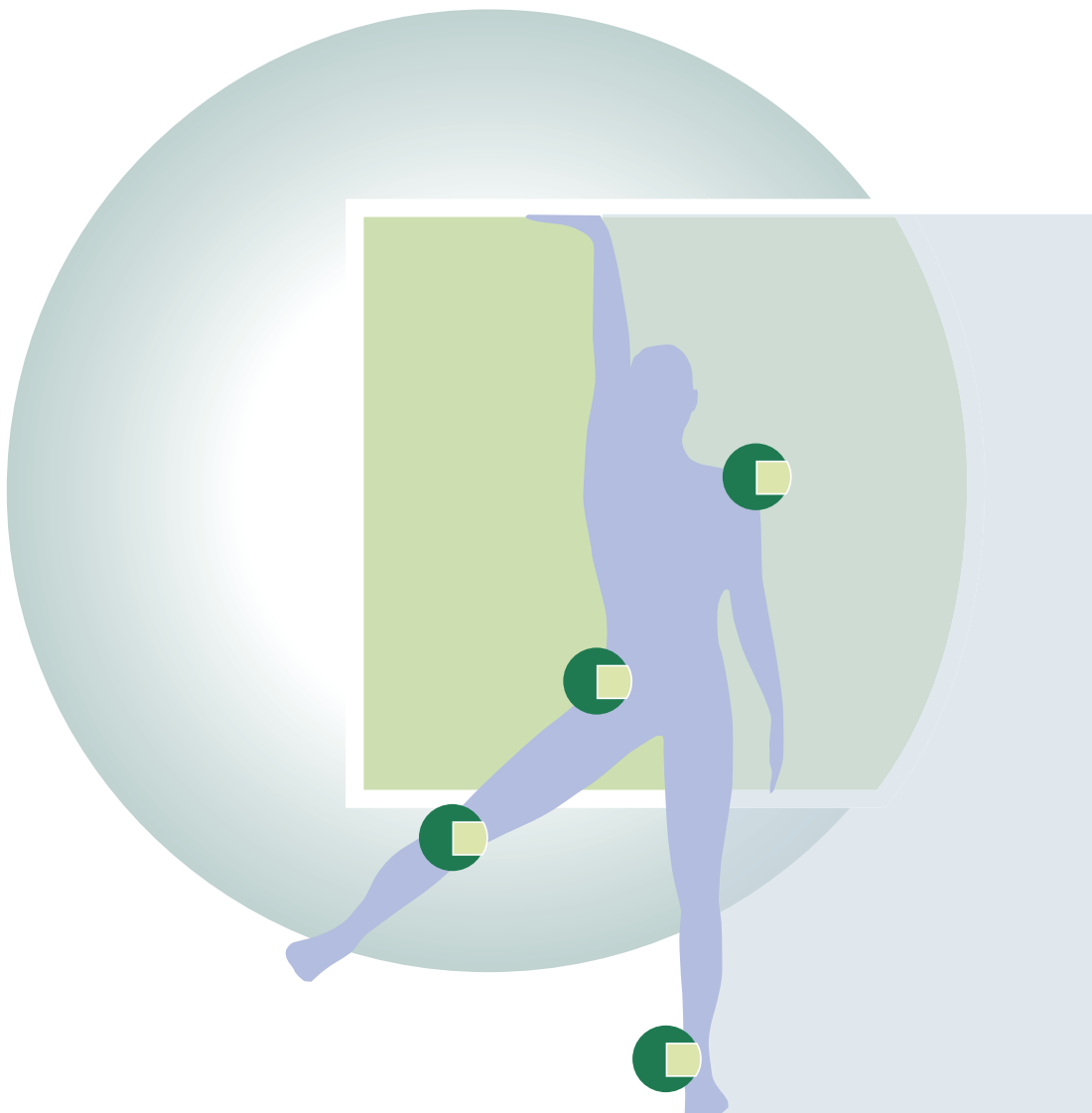
Immunohistochemical analysis of type II collagen. Collagen type II immunostaining is strongly positive in the superficial portion of the regenerated tissue, demonstrating that newly-formed tissue differentiation into hyaline articular cartilage occurred.

Indications

MaioRegen is indicated in all cases where it is necessary to restore osteo-cartilaginous connective tissue in the joints, in particular in the treatment of:

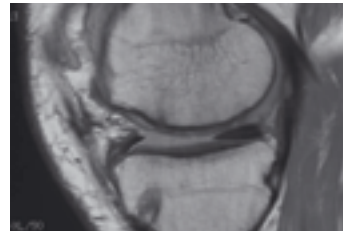
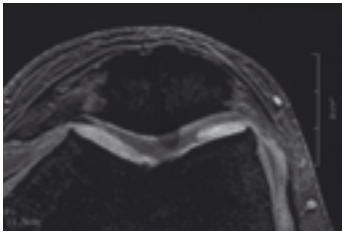
- osteo-chondral lesions of traumatic, post-traumatic, degenerative origin or due to osteochondritis dissecans;
- III-IV grade lesions (Outerbridge classification);
- focal, single or multiple lesions.

MaioRegen should not be used in patients with advanced osteoarthritic conditions, immune system disorders, neoplastic diseases, infectious diseases, obesity (BMI > 30) or above 60 years of age.



A selection of cases taken from a clinical study performed by Prof. M. Marcacci - Istituti Ortopedici Rizzoli in Bologna, Italy.

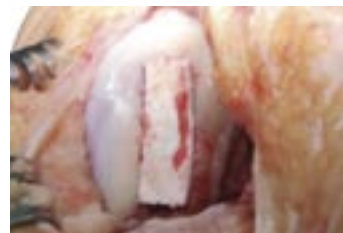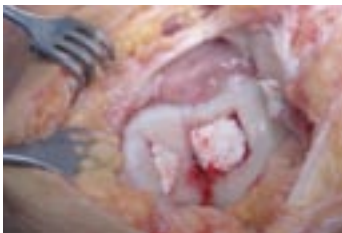PRE-OP



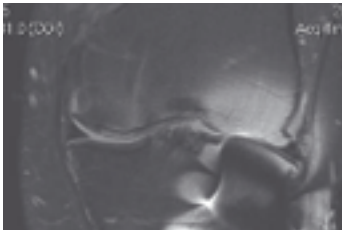Male, 46 years old.

Grade IV Multiple trochlear and medial femoral condyle lesions of traumatic origin on the left knee, treated with MaioRegen. MRI at 6 months and 1 year after surgery display complete regeneration of the osteo-cartilaginous defects and restored joint surface.

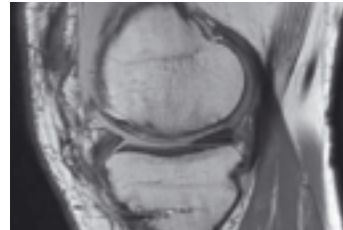
INTRA-OP



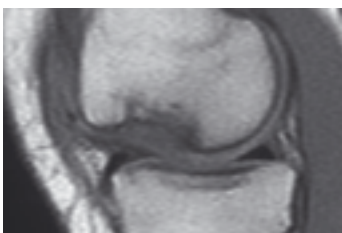POST-OP - 6 months



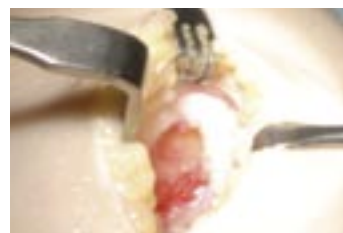POST-OP - 1 year



PRE-OP



INTRA-OP

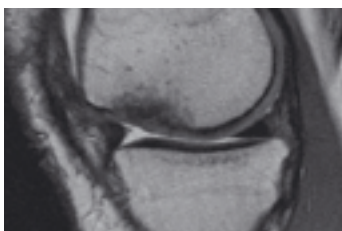


Female, 25 years old.

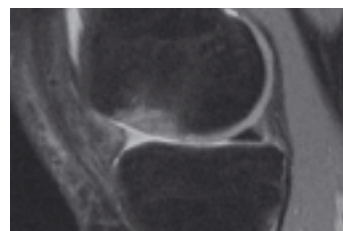
Grade IV focal lesion of traumatic origin in the lateral femoral condyle

of the left knee, treated with MaioRegen. The follow-up (MRI at 6 months and 1 year post-op) displays progressive regeneration of the osteo-cartilaginous defect.

POST-OP - 6 months



POST-OP - 1 year



Shapes and sizes



Ready-to-use and easy to apply through a "one-step" procedure.
MaioRegen osteo-chondral substitute is available in single sterile packages.

- **01600270** **MaioRegen**
Osteo-chondral substitute 3,5 x 3,5 x 0,6 cm
- **01600271** **MaioRegen**
Osteo-chondral substitute 5,0 x 5,0 x 0,6 cm



Finceramica

Regenerative surgery



Fin-Ceramica Faenza S.p.A.

Production facilities: Via Ravennana, 186 - 48018, Faenza (RA), Italy

Legal office: Via Granarolo, 177 / 3 - 48018, Faenza (RA), Italy

Ph. +39 0546 607311 - Fax +39 0546 607312

info@finceramica.it

www.finceramica.it